
PRESENTING CLINICAL SIGNS

DATE History: Heart murmur. Asymptomatic. Pre-anesthetic evaluation.

9/3/21 **ECHOCARDIOGRAPHIC FINDINGS**

2D, M-mode, and Doppler study.

PERFORMED BY: Left atrial size is normal. The mitral valve leaflets are mildly thickened and exhibit mild systolic prolapse. There is Doppler evidence of mitral regurgitation present. Left ventricular dimensions are normal. Left ventricular systolic function is hyperdynamic. The aorta and aortic valve are normal. Right atrial and right ventricular dimensions are normal. The tricuspid valve leaflets are mildly thickened, and there is Doppler evidence of tricuspid regurgitation present. TR velocity does not suggest the presence of pulmonary hypertension. The pulmonary artery and pulmonic valve are normal. No shunting lesions are visualized. No pericardial effusion or cardiac masses are seen.

Dr. Meredith Swart

INTERPRETED BY

Keith Blass, DVM,
MS, DACVIM
(Cardiology)

PATIENT

Bentley Frawley

SPECIES

Canine

ASSESSMENT/RECOMMENDATIONS

Degenerative mitral and tricuspid valve disease

BREED

Maltese

This examination demonstrates regurgitation of blood across Bentley's mitral and tricuspid valves resulting from degenerative valve disease. The hemodynamic effects of each of the regurgitations appear to be mild, as Bentley does not have secondary dilation of any of his cardiac chambers. As such, Bentley's valvular diseases appear to be well-compensated, and his current risk for the development of clinical signs secondary to them appears to be low.

SEX

MN

Bentley's cardiovascular risk for general anesthesia is only mildly increased based on this exam, though I do recommend avoiding the use of alpha-2 agonists in the anesthetic protocol and reducing the IV fluid rate by 25% as precaution. If possible, monitoring of heart rhythm, blood pressure, and pulse oximetry are recommended during the procedure.

AGE

13 y

No therapy is recommended at this stage of Bentley's valvular diseases.

A recheck echocardiogram is recommended in ~6 months to monitor for disease progression.

WEIGHT

8 lb

HOSPITAL NAME

Swart Veterinary
Imaging

REFERRING VET

Dr. Swart



DATE

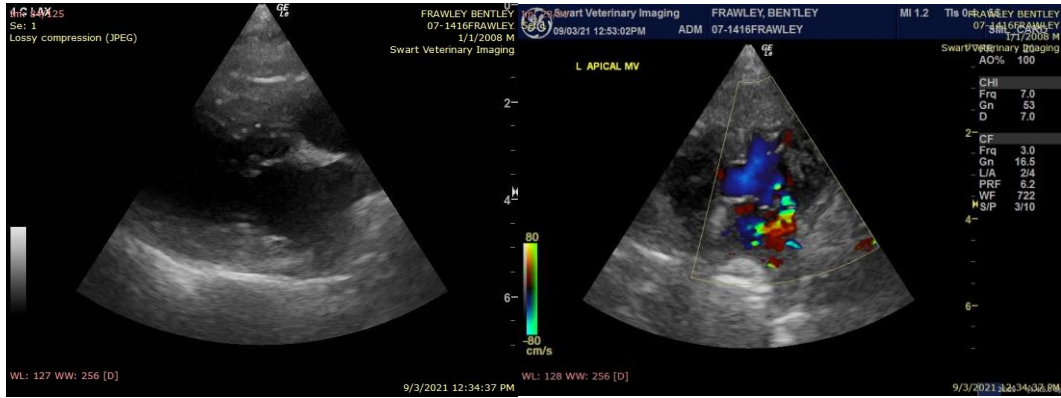
9/3/21

PERFORMED BY:

Dr. Meredith Swart

INTERPRETED BY

Keith Blass, DVM,
MS, DACVIM
(Cardiology)



The information and recommendations provided are based on the images presented by the referring veterinarian. No evaluation can be communicated regarding pathology that was not visible in the image/video clips provided.

PATIENT

Bentley Frawley

Thank you for this referral. If the clinical or image interpretation does not parallel your findings or if I can be of any further assistance please contact me.

SPECIES

Canine

Keith Blass, DVM, MS, DACVIM (Cardiology)
KeithBlass@gmail.com
631-804-5754

BREED

Maltese

SEX

MN

AGE

13 y

WEIGHT

8 lb

HOSPITAL NAME

Swart Veterinary
Imaging

REFERRING VET

Dr. Swart